

Special Issue: Cognition in Neuropsychiatric Disorders

Obsessive-compulsive disorder: beyond segregated cortico-striatal pathways

Mohammed R. Milad¹ and Scott L. Rauch^{1,2}

¹ Department of Psychiatry, Massachusetts General Hospital and Harvard Medical School, Charlestown, MA 02129, USA

² McLean Hospital, Belmont, MA 02478, USA

Obsessive-compulsive disorder (OCD) affects approximately 2–3% of the population and is characterized by recurrent intrusive thoughts (obsessions) and repetitive behaviors or mental acts (compulsions), typically performed in response to obsessions or related anxiety. In the past few decades, the prevailing models of OCD pathophysiology have focused on cortico-striatal circuitry. More recent neuroimaging evidence, however, points to critical involvement of the lateral and medial orbito-frontal cortices, the dorsal anterior cingulate cortex and amygdalo-cortical circuitry, in addition to cortico-striatal circuitry, in the pathophysiology of the disorder. In this review, we elaborate proposed features of OCD pathophysiology beyond the classic parallel cortico-striatal pathways and argue that this evidence suggests that fear extinction, in addition to behavioral inhibition, is impaired in OCD.

The current model of OCD

Intrusive thoughts, doubts, or concerns about safety, cleanliness, sex, violence, or symmetry, and urges to count or check ‘to be sure’ are common thoughts, feelings and behaviors that represent universal human experience to one degree or another. Healthy adaptive human function requires an ability to regulate and inhibit such intrusive thoughts, urges, feelings and behaviors. People with OCD are unable to control their thoughts and feelings and, consequently, experience obsessions accompanied by anxiety; typically, they also engage in associated compulsions, such as repetitive, stereotyped or ritualized behaviors, apparently designed to neutralize the anxiety associated with their obsessions. Thus, one perspective conceptualizes OCD as a model disorder of self-regulation and behavioral inhibition. Modern cognitive neuroscience has provided experimental tools, including neuroimaging methods, to examine the brain basis of self-regulation and behavioral inhibition.

A convergence of neuroscience research points to the involvement of cortico-striatal circuits (or loops; [Figure 1](#)) in behavioral control functions [1]. The anatomy and chemistry of cortico-striato-thalamo-cortical (CSTC) pathways were well established during the latter half of the 20th

century [2]. Progressive knowledge of this circuitry formed a popular basis for heuristic models of neuropsychiatric diseases, from classic movement disorders involving the basal ganglia to a range of psychiatric conditions [3–5]. In principle, the general organizing theme of these circuits is that they project from specific territories in frontal cortex, to corresponding targets within striatum, and then via direct and indirect pathways through the basal ganglia to the thalamus, and finally with recurrent projections back to the original frontal territory where each loop started [2] ([Figure 2](#)).

The emergence and evolution of modern brain imaging methods provided an opportunity to establish and refine

Glossary

Cognitive behavioral therapy (CBT): a type of psychotherapy commonly utilized for the treatment of anxiety and mood disorders. The general focus of this therapy is to aid patients in restructuring their thinking patterns, to reduce unhelpful and/or unrealistic thoughts using cognitive (i.e. reappraisal) approaches and to modify behavioral responses, such as through graded exposure to fear-provoking stimuli and situations.

Deep brain stimulation (DBS): an intervention currently used for treatment of severe, otherwise treatment-refractory, OCD (under a humanitarian device exemption, from the US Food and Drug Administration). This modern technology enables the chronic electrical stimulation of deep brain regions via surgical implantation of fine electrodes into the targeted brain region, connected to an implanted power source. DBS has also been approved for Parkinson’s disease, and is being actively studied for additional neuropsychiatric indications, such as major depression. Various indications for DBS involve stimulation of different regional brain targets.

Error monitoring: refers to the cognitive process of monitoring and responding to one’s own errors during the performance of a task.

Fear conditioning: laboratory fear conditioning is an experimental paradigm used to teach animals or humans to form an association between a neutral stimulus (e.g. a light or a tone) and an aversive unconditioned stimulus (US; e.g. a mild electric shock). The presentation of the now conditioned stimulus (CS) triggers the organism to exhibit several physiological responses. Most commonly measured conditioned responses are freezing and potentiated startle in rodents, and skin conductance and potentiated startle responses in humans.

Fear extinction: a training phase in conditioning studies that occurs after fear conditioning. During fear extinction, the cue (the CS) is repeatedly presented in the absence of the US. This extinction training (or within-session extinction learning) leads to decrement of the conditioned responses over trials. Subsequent test of the extinction learning after a delay (i.e. 24 hours) is referred to as extinction recall (or retention) test.

Obsessive compulsive disorder (OCD): a disorder characterized by intrusive, unwanted thoughts (i.e. obsessions) and ritualized, repetitive behaviors (i.e. compulsions). The obsessions are commonly accompanied by anxiety that drives the compulsions. The compulsions, therefore, are performed to neutralize and attenuate the obsessions and anxiety.

Corresponding author: Milad, M.R. (milad@nmr.mgh.harvard.edu).

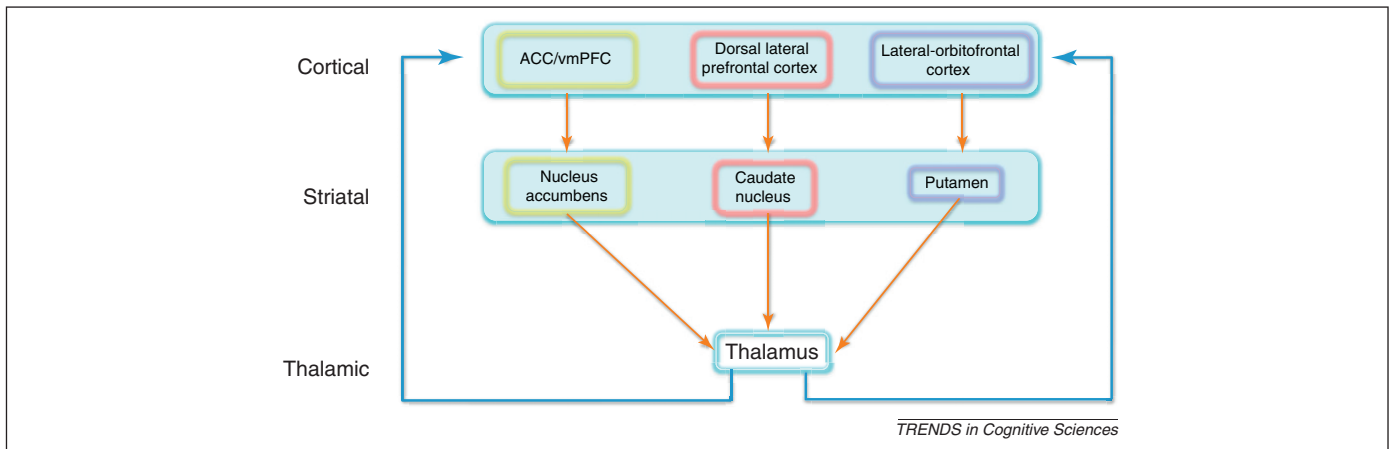


Figure 1. Schematic illustration of the different components of the cortico-striato-thalamo-cortical (CSTC) pathways commonly implicated in the psychopathology of obsessive-compulsive disorder (OCD). Abbreviations: ACC, anterior cingulate cortex. vmPFC, ventromedial prefrontal cortex.

neurocircuitry models of OCD. Early functional neuroimaging studies of OCD predominantly examined differences in indices of regional brain function between affected subjects and psychiatrically healthy comparison groups, while at rest or during neutral states (e.g. [6–8]). Subsequent research studied subjects with OCD before and after standard courses of treatment, such as with serotonergic reuptake inhibitors or cognitive-behavioral therapy (e.g. [9,10]). Complementary approaches entailed studying subjects with OCD during provocation of their symptoms (e.g. while being exposed to triggers, such as a contaminated object or provocative pictures [11–13]). Convergent findings from such studies implicated the CSTC pathways in the

pathophysiology of OCD; activity in the nodes of this circuit was elevated at rest, accentuated during symptom provocation and attenuated toward normal with successful treatment [14,15].

As the fields of cognitive-affective neuroscience and brain imaging advanced in tandem, more powerful approaches evolved to better examine the substrates of psychiatric diseases. Using such approaches, and building on earlier findings in OCD, investigators next used cognitive neuroscience methods in combination with functional imaging tools to test the involvement of specific neural networks within the CSTC in the context of specific cognitive-affective paradigms [16–19]. This approach enabled

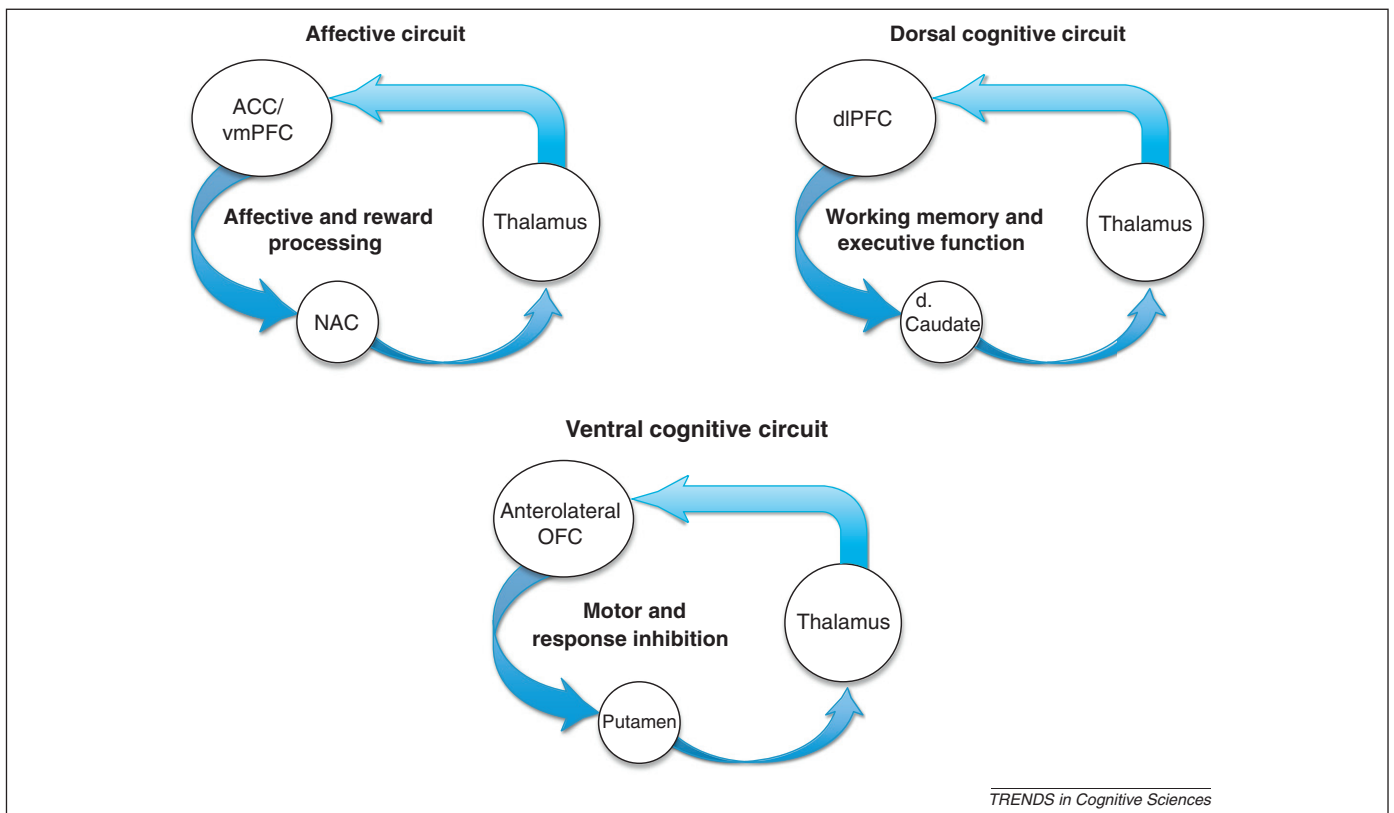


Figure 2. Schematic diagram illustrating the so-called 'cortico-striatal loops' as commonly defined. Abbreviations: dlPFC, dorsolateral prefrontal cortex; NAC, nucleus accumbens; OFC, orbitofrontal cortex; d. Caudate, dorsal caudate.

better-controlled experiments and also an avenue for bringing together a more granular analysis of pathophysiology with a more sophisticated approach to functional anatomy, delving into subterritories and specific loci within named brain regions.

In this review, we highlight how the recent advances in cognitive-affective neuroscience may help formulate an updated conceptualization of OCD. We emphasize: (i) the distinct roles that the lateral and medial orbitofrontal cortices (lOFC and mOFC, respectively) may play in reward processing and affect regulation; (ii) the role of dorsal anterior cingulate cortex (dACC) in error processing and its potential role in fear expression; and (iii) the role of amygdalo-cortical circuitry in the expression and regulation of fear. We end with a discussion regarding future potential applications of this knowledge to advance treatment for OCD. We note that, in this article, we will not conduct a comprehensive review of the OCD literature. We do, however, highlight some of the recent advances and findings related to structural imaging in OCD (Box 1) and findings related to systems involved in implicit versus explicit learning and how these findings may relate to the phenomenology of OCD (Box 2).

Why is the CSTC model insufficient?

Early characterizations of CSTC loops emphasized their parallel and segregated nature, emanating from various frontal subterritories and ramifying in specific striatal

Box 1. Structural imaging in OCD

Structural imaging studies continue to evolve and use novel methodological tools to assess the structural integrity of brain regions implicated in the pathophysiology of OCD. Some of those studies focus on gray matter volume or thickness, whereas others focus on the white matter and fiber tracts connecting the different components of the striatum and the PFC in patients with OCD. Furthermore, some use a whole-brain analysis approach, whereas others use region of interest analysis based on the CSTC model. Several excellent reviews and meta-analyses focusing on structural imaging of OCD have recently been published [22,90]. Below, we highlight some of the most consistent as well as the inconsistent findings in this domain.

Given the major emphasis on the OFC in the pathophysiology of OCD, several studies have primarily focused on examining anatomical differences in this brain region between healthy controls and patients with OCD. The early studies that focused on a region-of-interest analysis approach consistently reported reduced OFC volume in patients with OCD (reviewed in [22]). A recent meta-analysis found no evidence of significant structural alterations in the OFC in patients with OCD, [90] and another study suggested that potential structural changes in the OFC within OCD may be compensatory [91]. As for the striatum in OCD, several studies reported increased gray matter volume (e.g. [92]), whereas other studies, using a region-of-interest approach, reported significant volumetric reductions in the caudate [22]. Unlike the striatum and the OFC, however, findings with regards to structural abnormalities in the dACC appear to be consistent, regardless of the methods utilized. The consistent finding is that dACC gray matter volume is significantly reduced in patients with OCD (e.g. [90]). With respect to white matter abnormalities, a few studies using diffusion tensor imaging (DTI) reported abnormalities in OCD involving a variety of white matter tracts, such as the cingulum bundle, the anterior limb of the internal capsule [93,94] and corpus callosum [94,95]. However, the nature of these abnormal DTI findings has not been consistent.

Box 2. Is OCD psychopathology associated with multiple memory system dysfunction?

One key function of the cortico-striatal circuit is the mediation of implicit (or procedural and/or habit) learning. Cortico-temporal lobe circuits, by contrast, mediate more explicit (i.e. conscious) types of learning. Given the dysfunction of CTSC circuits in OCD, several studies have been conducted to compare and contrast implicit versus explicit forms of learning in patients with OCD. In the serial reaction time (SRT) paradigm, commonly used to assess implicit learning, a visual cue appears on a computer screen in one of four positions. The participant is instructed to press a button corresponding to the location of the cue as fast as possible. Two types of trial block are usually presented: a random block (in which the cue appears at random locations) and an implicit sequence block (during which a pattern of locations repeats). Although participants are not consciously aware of the sequence, their reaction time in the implicit sequence block improves over trials, indicative of facilitated implicit procedural learning. The performance of this task reliably activates cortico-striatal networks in healthy individuals [96]. In patients with OCD, deficient performance in this task has been reported, although the presence or absence of the deficiency at the behavioral level appears to depend on the memory load of the participant [16,46,97]. At the functional level, however, the pattern of activation induced by this and similar tasks shifts from cortico-striatal to cortico-hippocampal in patients with OCD [16,98]. These studies inspired the formulation of a model to suggest that the CSTC system that mediates non-conscious information processing is deficient in OCD, and that the observed hippocampal (in the case of the SRT) activity may represent a compensatory mechanism, leveraging (fronto-hippocampal) circuitry that is normally responsible for conscious information processing. It is therefore proposed that this could explain why, in OCD, information normally processed outside of consciousness intrudes into the conscious domain (i.e. obsessions), as a consequence of the core CSTC deficit together with fronto-hippocampal compensation [96].

There is another emerging cognitive model for OCD that is also based on a multiple memory system heuristic [99]. Briefly, activity of a goal-directed system normally drives individuals to maintain actions to obtain a preferred outcome. The repetition of this goal-directed behavior normally results in a shift to a second habit-mediating system, thereby allowing for greater efficiency by optimizing uncommitted functional capacity in the cognitive and/or goal-directed system. It has recently been proposed that OCD may result from dysfunction in the goal-directed response system, thus necessarily increasing the reliance on the habitual responding system, which manifests as compulsive behavior [100].

subterritories. For instance, one heuristic, dubbed ‘the striatal topography model of OCD and related disorders’, posited that comparable striatal pathology could explain the relationship between OCD and Tourette syndrome (TS); whereby OCD was the result of pathology within the caudate, disrupting OFC/ACC-caudate function, whereas TS was the result of pathology within the putamen, disrupting sensorimotor-putamen function [20]. Anatomical evidence, however, now indicates that the cortico-striatal loops are in fact much more integrated within the striatum and the thalamus and not fully segregated as initially thought; rather the anatomy is better described as a spiral, with information cascading from one loop to the next [21]. Moreover, the CSTC model does not take into consideration the role of the amygdala and the hippocampus and their interaction with the frontal cortex in mediating fear and anxiety in patients with OCD. Furthermore, imaging findings of the past decade have made clear that such heuristic models of OCD and TS pathophysiology represent a gross oversimplification, which is not born

out by the data [22]. Finally, whereas the early CSTC model of OCD placed heavy emphasis on the role of the OFC generically, it is now appreciated that different subregions of the OFC play distinct and disparate roles in processing reward, negative affect, and specifically fear and anxiety [23,24].

The mOFC and IOFC

An extensive meta-analysis of OFC function associates the IOFC with processing negative valence and the mOFC with processing positive valence [24]. More specifically, the IOFC appears critical in responding to punishment and escape from danger, and may be involved in ritualized behavioral responses [25–27]. The mOFC, by contrast, appears more involved in emotion regulation and reward processing. Extensive research conducted in rodents and healthy humans now implicates the ventromedial prefrontal cortex (vmPFC), extending to the mOFC in the regulation of fear, especially during the recall of safety memories [28]. Lesion studies in rodents [29] and monkeys result in impaired fear extinction and compulsive-like behavior in bar-pressing for food [30]. The mOFC has also been implicated in olfactory aversive conditioning and reversal of conditioning contingency during classical conditioning [31]. The function of the mOFC and adjacent vmPFC correlate with the magnitude of fear extinction memory in healthy humans [32,33].

In OCD, most of the early positron emission tomography (PET) studies that examined resting metabolic state, used symptom provocation paradigms, and assessed pre-post treatments have implicated the OFC in the pathophysiology of OCD without explicit distinction between the mOFC versus the IOFC (reviewed in [14,34]). The distinction between IOFC and mOFC dysfunction in OCD was suggested, however, by an early PET study reporting that OCD symptoms were positively correlated with metabolism in the anterolateral OFC and were negatively correlated with posteromedial OFC regions [11]. Subsequent functional magnetic resonance imaging (fMRI) studies reported positive correlations between hyperactivation of the IOFC and OCD symptom severity during the performance of the serial reaction time task [16] and during symptom provocation [35,36]. Studies of OCD treatment response have shown that IOFC hyperactivity prior to therapy predicts the subsequent response to serotonergic reuptake inhibitors; the lesser the magnitude of OFC hyperactivity, the better response to treatment [37].

In contrast to the IOFC, the mOFC appears hypoactive in OCD. One hypothesis regarding the pathophysiology of OCD is that the disorder is characterized by dysfunctional inhibitory control [38]. Indeed, neuroimaging studies report hypoactive mOFC in OCD and that symptom severity appears to be inversely correlated with mOFC function [16,23]. This is consistent with the idea that the elevated fear and anxiety in OCD may be to the result of failure to activate the vmPFC/OFC when faced with stimuli that trigger OCD-related fears [39].

Several studies, however, seem to contradict the hyperlateral, hypo-mOFC model suggested above. For example, some of the earlier PET studies reported enhanced

resting metabolism in fairly medial portions of the OFC in patients with OCD (reviewed in [22,34]). Recent fMRI studies also report significantly increased activation of the vmPFC in patients with OCD engaged in an error-interference task while the motivational context of the task is varied in relation to committing an error (i.e. gaining vs losing money) [19,40]; a finding replicated in a pediatric cohort with OCD [41]. Using cognitive and reward reversal tasks and fMRI, some studies reported hypoactivation of the IOFC when OCD subjects were asked to learn that a new object represents the correct answer in the reversal task [42,43]. The reasons for these apparent inconsistencies may be because of several factors including differences in the paradigms and tools used, the heterogeneity of the disorder, comorbidities and the presence or absence of medications while patients with OCD are participating in the study. Regardless of the apparent discrepancies, all of the above studies suggest that lateral and medial portions of the OFC are indeed dysfunctional in OCD, and that these regions are playing different roles in the disorder.

The ACC: error processing and fear expression

The dACC is involved in numerous cognitive and affective functions, and is particularly relevant to OCD psychopathology. This brain region is involved in detecting the presence of cognitive conflict, and error monitoring and detection [44,45]. Common paradigms used to test the function of the dACC use an element of interference such that there are two conditions: congruent versus incongruent. Response to the congruent condition represents a prepotent or automatic response that is easy to perform. The incongruent condition requires the inhibition of the automatic/prepotent response in favor of the more challenging response; hence represents a conflict to the participant. The function of the dACC has commonly been assessed when subjects are about to respond (assessment of conflict) and during the period after the subject has responded (potential period where subjects would have realized that an error was committed). These tasks include variants of the Stroop, go/no-go, and multi-source interference tasks [46–48]. There exists an extensive literature using fMRI (reviewed in [47]) and electrophysiological tools (i.e. measuring event-related potential) [49] on the utilization of these paradigms that shows increased activation of the dACC when contrasting the incongruent versus the congruent condition, thus supporting its role in the assessment and/or detection of interference or conflict [50]. Failing to suppress the prepotent responses in antisaccade tasks where subjects are instructed to look away from a stimulus presented on a computer screen leads to activation of the dACC [51]. In OCD, several studies show hyperactivation of the dACC in response to the incongruent relative to the congruent conditions [19,41,52–55]. Moreover, task-induced functional connectivity analysis in patients with OCD performing the Stroop task revealed significantly enhanced connectivity between dACC and the dorsolateral prefrontal cortex, supporting the idea of abnormal error processing in patients with OCD and a cortico-cortical interaction that may adversely affect decision making in OCD [55].

In addition to error and conflict monitoring, the dACC may also be critical for the expression of conditioned fear. Fear conditioning studies have previously noted dACC activation [33,56], but the significance of this response as a predictor of fear was not highlighted. In recent years, neuroimaging studies have specifically focused on the dACC in fear expression. As with the relationship between vmPFC and extinction recall, cortical thickness and activation of the dACC positively correlates with psychophysiological measures of fear learning (Galvanic skin responses) during fear conditioning. Moreover, dACC is activated during presentation of conditioned as well as unconditioned cues, suggesting a role in fear expression [57,58].

In patients with OCD, lesions of the dACC (e.g. anterior cingulotomy) have been shown to significantly reduce OCD symptom severity in those patients with severe, otherwise treatment-refractory, illness [59]. Moreover, successful treatment of OCD with serotonergic reuptake inhibitors has been found to reduce dACC metabolism [60]. These data are significant in implicating the dACC in addition to the OFC-striatal circuits, in the pathophysiology of OCD. Perhaps hyperactivation of the dACC mediates faulty error signals that contribute to the obsessions observed in OCD. An alternative hypothesis is that hyperactivation of the dACC in OCD may mediate the elevated fear and anxiety observed in this disorder. Future studies should examine the role of the dACC in fear conditioning and expression in the OCD population to test this hypothesis.

The amygdala and OCD

Although the amygdala responds to novelty, salience and a variety of emotional stimuli, its role in mediating fear and anxiety is the most commonly referenced [61]. In fact, the amygdala is often referred to as the hub of fear. A variety of experimental designs have been employed to test the role of the amygdala in fear and anxiety; these include the presentation of emotional faces, international affective picture system (IAPS) stimuli and classical fear conditioning. Such paradigms have been consistently shown that presentation of negatively valenced stimuli (implicitly or explicitly) activate the amygdala in healthy individuals [62–64]. Moreover, consistent with prevailing hypotheses, exaggerated amygdala responses have often been observed in disorders characterized by excessive or inappropriate fear expression [65,66].

Across the anxiety disorders, however, aberrant amygdala function does not seem to be present uniformly under all circumstances [65]. For example, in post-traumatic stress disorder, hyperactivation of the amygdala is present in response to stimuli with negative valence, and during fear conditioning as well as symptom provocation [67,68]. In specific phobia, however, although disorder-specific stimuli (e.g. phobic stimuli) do yield exaggerated amygdala responses [69,70], general threat-related stimuli (e.g. emotional faces) do not [71]. Interestingly, OCD appears to exhibit a unique profile in this regard; although OCD-specific stimuli have been associated with exaggerated amygdala responses [12,36,72], non-specific emotional stimuli (e.g. faces) actually yield lesser amygdala responses compared with responses in healthy comparison subjects [17]. Comparable findings have also been reported in a

pediatric OCD sample [73]. However, one recent study found increased amygdala activation in patients with OCD during active responses to emotional faces [74]. Another study reported that, although amygdala hyperactivation was observed in response to symptom-provoking stimuli, such hyperactivation was also noted in response to negative stimuli unrelated to the OCD symptoms [12]. Thus, it is important to note that the role of the amygdala in the pathophysiology of OCD is in need of additional investigation to clarify whether, or when, amygdala dysfunction in OCD is related to OCD-specific versus non-specific emotional stimuli.

What is next in OCD research?

The past decade has witnessed expansive growth in neuroimaging and cognitive-behavioral neuroscience. Below, we highlight two prospective areas of research that may be ripe for additional advancements in knowledge regarding the neural basis of OCD and in the development of novel therapeutic approaches.

Interrogation of the neural circuitry mediating fear extinction in OCD

The neurobiology of fear extinction is increasingly well delineated and involves the interaction between the vmPFC/mOFC, dACC and amygdala [75,76], key structures implicated in OCD pathophysiology as noted above. Thus, the profile of regional brain dysfunction and clinical presentation of OCD prompt the hypothesis that fear extinction may be impaired in patients with OCD. Figure 3 represents a meta-analysis of studies reporting significant findings within nodes of the fear extinction network during fear learning, fear extinction and extinction recall (see the supplemental material online for more details). This figure highlights the overlap between the brain regions implicated in fear learning and its subsequent extinction and several of the brain regions implicated in the pathophysiology of OCD, including the dACC, vmPFC, thalamus, amygdala and hippocampus. There are, however, no published studies examining fear extinction and its retention in OCD. Consonant with a growing interest in fear conditioning and/or extinction in anxiety disorders research [28], we propose that examining fear conditioning and extinction circuits in patients with OCD could be beneficial for understanding the pathogenesis, pathophysiology and treatment of OCD. It could be argued, however, that the fear extinction model may be a better fit for understanding other anxiety disorders, such as post-traumatic stress disorder, and does not necessarily represent or explain the etiology, phenomenology and psychopathology of OCD. Indeed, the impaired fear extinction in OCD that we hypothesize herein is not intended to explain the reasons for why one develops OCD and are not intended to explain the entire complex phenomenology of OCD. Rather, given that (i) the elevated fear and anxiety observed in OCD may be causal in driving or sustaining some of the compulsions, and (ii) the neural circuits mediating fear extinction and those implicated in psychopathology of OCD overlap, we anticipate that understanding the neural circuits mediating fear extinction in OCD patients may be particularly useful for several reasons.

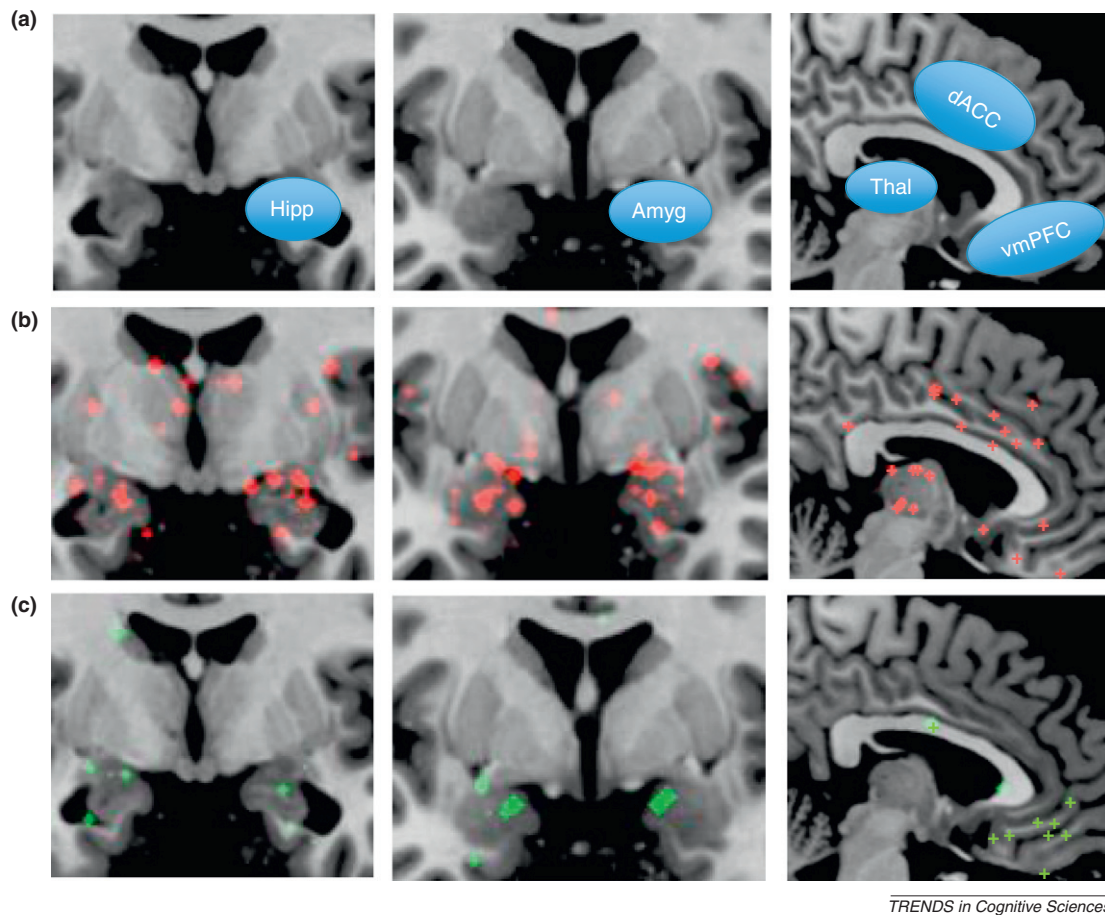


Figure 3. Brain regions involved in fear conditioning, extinction learning and recall appear to overlap with brain regions implicated in the psychopathology of obsessive-compulsive disorder (OCD). **(a)** Anatomical illustration of brain regions commonly implicated in OCD. Abbreviations: Hipp, hippocampus. Amyg, amygdala. Thal, thalamus. dACC, dorsal anterior cingulate cortex. vmPFC, ventromedial prefrontal cortex. Striatal regions are not illustrated in blue shapes for simplicity, but are clearly visible. **(b)** and **(c)** represent results from a meta-analysis focusing on functional neuroimaging studies of fear conditioning **(b)**, extinction learning and recall **(c)**. Crosses displayed on the anatomical images represent change in functional activation during fear conditioning (red) and extinction (green) regardless of the direction of activation (increased or decreased), and includes studies that examined patients with disorders. Structural imaging studies were not included in this meta-analysis. For additional details, see the supplemental material online.

First, cognitive behavioral therapy (CBT) is currently among the most effective treatments for OCD. CBT and other forms of exposure therapies rely on extinction mechanisms [77]. Thus, such studies would allow for understanding the neural mechanisms underlying one of the most effective treatments for OCD and other anxiety disorders. Second, a key feature of OCD is the inability to inhibit or extinguish fear associated with obsessions [78]. Individuals with OCD avoid fear-provoking situations and stimuli, and often cope with them by developing avoidance strategies to protect themselves; thus hindering fear extinction from occurring. Hence, although not accounting for the etiology of OCD, fear extinction may be a valid model of the major maintaining factor in OCD. Examining fear extinction in OCD could therefore allow for measuring neural responses involved in the pathogenesis and maintenance of OCD. A third advantage of using fear extinction paradigms in studying OCD psychopathology is the capacity for conducting animal studies that are complementary to human neuroimaging studies of fear extinction [28]. The cross-species validity of the extinction model therefore allows the use of rodents to address questions that are not possible to answer directly in humans.

It is important to note that translational fear extinction research has led to the development of novel therapeutic approaches that are being examined with promising results, such as reconsolidation blockade [79,80] and adjuncts to CBT, such as D-cycloserine (DCS) [81]. DCS has in fact been used as an adjunct to CBT in patients with OCD, with positive clinical outcome in some [82,83] but not in all studies (probably because of variance in dosage or experimental procedures) [84]. Perhaps further research bridging rodents and humans could help elucidate why DCS is effective in some experimental conditions but not others, or otherwise help to develop novel or improved therapies for OCD. Thus, learning about the neural circuits of fear extinction in OCD could elucidate how the fear and anxiety induced by obsessions are sustained, reveal new opportunities or targets for therapeutic intervention and provide a model system for exploring strategies for augmentation or relapse prevention with regard to CBT.

Enhancing treatment for OCD

One of the primary objectives in examining the neurobiology of OCD is to advance the development of more effective treatments. Behavioral (i.e. CBT) and pharmacological

interventions are established as effective for OCD and have been used for decades [85]. Still, a significant proportion of patients are left with substantial residual symptoms. A variety of alternative strategies have been explored for treatment-resistant OCD.

Most pertinent to neurocircuitry models of OCD are surgical and neurostimulation modalities that are reserved for the most severely ill and explicitly represent intervention at the level of regional brain function and/or structure. For instance, modern ablative neurosurgical procedures entail lesions at specifically targeted loci within the brain, such as the dACC in anterior cingulotomy. Furthermore, gamma knife technology has been used to create lesions for smaller targets, such as in anterior capsulotomy, thereby circumventing the need for craniotomy [86]. More recently, deep brain stimulation (DBS), involving the implantation of electrodes, has enabled chronic stimulation of targeted brain areas. In OCD, multiple DBS targets have been studied and are currently utilized in DBS treatment. Those include the anterior limb of the internal capsule, the ventral capsule/ventral striatum (VC/VS) the subthalamic nucleus and the nucleus accumbens [86,87]. The aim of the stimulation in OCD has been conceptualized in some instances to achieve disruption of the overactive cortico-striatal loops.

Although the results of invasive neurotherapeutic interventions for OCD have been encouraging in some instances, the risks are significant and only a proportion of patients exhibit a positive response [59,88]. Therefore, it is appealing to consider that cognitive neuroscience and imaging methods could be used to enhance outcomes in two ways. First, such methods could be used to identify predictors of treatment response as an aid in patient selection [89]. Second, such tools could actually be used to guide the therapeutic intervention itself, such as by identifying optimal targets or optimal stimulation parameters in individual cases [86].

Concluding remarks

The cortico-striatal circuitry model of OCD pathophysiology emerged during the latter part of the 20th century and, for the past 25 years, has provided the principal platform for hypothesis-driven research in the field. Advances in neuroscience and progress in neuroimaging methods provided the means for extending and refining the original model. Specifically, (i) cortico-striatal loops are now understood to be interconnected rather than fully segregated, and OCD and related disorders may not exhibit pathology that maps neatly onto gross striatal subterritories; (ii) OFC is known to have meaningful functional subdivisions, such that hyperactivity in IOFC may mediate obsessions, and deficient mOFC function may be associated with limitations in extinction recall; (iii) dACC dysfunction in OCD may play a role in aberrant error monitoring and fear conditioning and/or expression; and (iv) fundamental differences in amygdala responsivity may mediate anxiety in OCD and yet distinguish this condition from other anxiety disorders. We propose that this framework prompts new testable hypotheses about how dysfunction in these brain regions may be related to deficient fear inhibition, severity of symptoms and predictors of treatment response. More-

Box 3. Questions for future research

- Would fear extinction deficiency be present in all subtypes of OCD or would it be present in some but not others?
- Could fear extinction capacity serve as a predictor of treatment response to CBT in OCD?
- Could the well-documented dysfunction in the different components of the striatum interfere or interact with fear extinction capacity in OCD?
- If fear extinction is in fact deficient in patients with OCD, will the underlying neural mechanisms of this deficiency be the same or different to that reported in other anxiety or psychiatric disorders (i.e. post-traumatic stress disorder or schizophrenia)?
- Could neuromodulation of vmPFC and/or mOFC fortify extinction capacity and, hence, CBT response in OCD?

over, this model suggests new targets for neuromodulatory treatments to enhance vmPFC and mOFC function with the aim of strengthening fear extinction; neutralizing dACC function to reduce error signaling; and attenuating excessive IOFC activity to mitigate unwanted obsessions and worries. Addressing some of these hypotheses and other related questions (Box 3) may be relevant to the evolving model of OCD pathophysiology as it provides a basis for a contemporary research agenda spanning imaging, cognitive-affective and clinical neuroscience.

Disclosure Statement

S.L.R. has participated in research funded by Cyberonics and Medtronic. M.R.M. has received consulting fees from MircoTransponder Inc.

Acknowledgments

M.R.M. is supported by NIH grants R01-MH081975, DoD grant W81XWH-11-2-0079 and the Judah Foundation. We would like to thank Katelyn Trecartin and Daria Boratyn for their efforts in generating the figures and their assistance in conducting the meta-analysis.

Appendix A. Supplementary data

Supplementary data associated with this article can be found, in the online version, at [doi:10.1016/j.tics.2011.11.003](https://doi.org/10.1016/j.tics.2011.11.003).

References

- 1 Di Filippo, M. *et al.* (2009) Short-term and long-term plasticity at corticostriatal synapses: implications for learning and memory. *Behav. Brain Res.* 199, 108–118
- 2 Alexander, G.E. *et al.* (1986) Parallel organization of functionally segregated circuits linking basal ganglia and cortex. *Annu. Rev. Neurosci.* 9, 357–381
- 3 Swerdlow, N.R., Obsessive-compulsive disorder and tic, syndromes. (2001) *Med. Clin. North Am.* 85, 735–755
- 4 Albin, R.L. *et al.* (1995) The functional anatomy of disorders of the basal ganglia. *Trends Neurosci.* 18, 63–64
- 5 Graybiel, A.M. and Rauch, S.L. (2000) Toward a neurobiology of obsessive-compulsive disorder. *Neuron* 28, 343–347
- 6 Baxter, L.R., Jr *et al.* (1987) Local cerebral glucose metabolic rates in obsessive-compulsive disorder. A comparison with rates in unipolar depression and in normal controls. *Arch. Gen. Psychiatry* 44, 211–218
- 7 Baxter, L.R., Jr *et al.* (1988) Cerebral glucose metabolic rates in nondepressed patients with obsessive-compulsive disorder. *Am. J. Psychiatry* 145, 1560–1563
- 8 Swedo, S.E. *et al.* (1989) Cerebral glucose metabolism in childhood-onset obsessive-compulsive disorder. *Arch. Gen. Psychiatry* 46, 518–523
- 9 Swedo, S.E. *et al.* (1992) Cerebral glucose metabolism in childhood-onset obsessive-compulsive disorder. Revisualization during pharmacotherapy. *Arch. Gen. Psychiatry* 49, 690–694

- 10 Baxter, L.R., Jr *et al.* (1992) Caudate glucose metabolic rate changes with both drug and behavior therapy for obsessive-compulsive disorder. *Arch. Gen. Psychiatry* 49, 681–689
- 11 Rauch, S.L. *et al.* (1994) Regional cerebral blood flow measured during symptom provocation in obsessive-compulsive disorder using oxygen 15-labeled carbon dioxide and positron emission tomography. *Arch. Gen. Psychiatry* 51, 62–70
- 12 Simon, D. *et al.* (2010) Fronto-striato-limbic hyperactivation in obsessive-compulsive disorder during individually tailored symptom provocation. *Psychophysiology* 47, 728–738
- 13 McGuire, P.K. *et al.* (1994) Functional anatomy of obsessive-compulsive phenomena. *Br. J. Psychiatry* 164, 459–468
- 14 Saxena, S. and Rauch, S.L. (2000) Functional neuroimaging and the neuroanatomy of obsessive-compulsive disorder. *Psychiatr. Clin. North Am.* 23, 563–586
- 15 Saxena, S. *et al.* (1998) Neuroimaging and frontal-subcortical circuitry in obsessive-compulsive disorder. *Br. J. Psychiatry Suppl.* 35, 26–37
- 16 Rauch, S.L. *et al.* (2007) Functional magnetic resonance imaging study of regional brain activation during implicit sequence learning in obsessive-compulsive disorder. *Biol. Psychiatry* 61, 330–336
- 17 Cannistraro, P.A. *et al.* (2004) Amygdala responses to human faces in obsessive-compulsive disorder. *Biol. Psychiatry* 56, 916–920
- 18 van den Heuvel, O.A. *et al.* (2005) Disorder-specific neuroanatomical correlates of attentional bias in obsessive-compulsive disorder, panic disorder, and hypochondriasis. *Arch. Gen. Psychiatry* 62, 922–933
- 19 Fitzgerald, K.D. *et al.* (2005) Error-related hyperactivity of the anterior cingulate cortex in obsessive-compulsive disorder. *Biol. Psychiatry* 57, 287–294
- 20 Rauch, S.L. *et al.* (1998) Neuroimaging and the neuroanatomy of PTSD. *CNS Spectr.* 3 (Suppl. 2), 30–41
- 21 Haber, S.N. and Knutson, B. (2010) The reward circuit: linking primate anatomy and human imaging. *Neuropsychopharmacology* 35, 4–26
- 22 Menzies, L. *et al.* (2008) Integrating evidence from neuroimaging and neuropsychological studies of obsessive-compulsive disorder: the orbitofronto-striatal model revisited. *Neurosci. Biobehav. Rev.* 32, 525–549
- 23 Milad, M.R. and Rauch, S.L. (2007) The role of the orbitofrontal cortex in anxiety disorders. *Ann. N.Y. Acad. Sci.* 1121, 546–561
- 24 Kringelbach, M.L. and Rolls, E.T. (2004) The functional neuroanatomy of the human orbitofrontal cortex: evidence from neuroimaging and neuropsychology. *Prog. Neurobiol.* 72, 341–372
- 25 Elliott, R. *et al.* (2010) Hedonic and informational functions of the human orbitofrontal cortex. *Cereb. Cortex* 20, 198–204
- 26 Hollerman, J.R. *et al.* (2000) Involvement of basal ganglia and orbitofrontal cortex in goal-directed behavior. *Prog. Brain Res.* 126, 193–215
- 27 O'Doherty, J. *et al.* (2003) Dissociating valence of outcome from behavioral control in human orbital and ventral prefrontal cortices. *J. Neurosci.* 23, 7931–7939
- 28 Graham, B.M. and Milad, M.R. (2011) The study of fear extinction: implications for anxiety disorders. *Am. J. Psychiatry* DOI: 10.1176/appi.ajp.2011.11040557
- 29 Quirk, G.J. *et al.* (2000) The role of ventromedial prefrontal cortex in the recovery of extinguished fear. *J. Neurosci.* 20, 6225–6231
- 30 Joel, D. *et al.* (2005) Impaired procedural learning in obsessive-compulsive disorder and Parkinson's disease, but not in major depressive disorder. *Behav. Brain Res.* 157, 253–263
- 31 Morris, J.S. and Dolan, R.J. (2004) Dissociable amygdala and orbitofrontal responses during reversal fear conditioning. *Neuroimage* 22, 372–380
- 32 Milad, M.R. *et al.* (2007) Recall of fear extinction in humans activates the ventromedial prefrontal cortex and hippocampus in concert. *Biol. Psychiatry* 62, 446–454
- 33 Phelps, E.A. *et al.* (2004) Extinction learning in humans: role of the amygdala and vmPFC. *Neuron* 43, 897–905
- 34 Baxter, L.R., Jr *et al.* (1996) Brain mediation of obsessive-compulsive disorder symptoms: evidence from functional brain imaging studies in the human and nonhuman primate. *Semin. Clin. Neuropsychiatry* 1, 32–47
- 35 Adler, C.M. *et al.* (2000) fMRI of neuronal activation with symptom provocation in unmedicated patients with obsessive compulsive disorder. *J. Psychiatr. Res.* 34, 317–324
- 36 Breiter, H.C. *et al.* (1996) Functional magnetic resonance imaging of symptom provocation in obsessive-compulsive disorder. *Arch. Gen. Psychiatry* 53, 595–606
- 37 Rauch, S.L. *et al.* (2002) Predictors of fluvoxamine response in contamination-related obsessive compulsive disorder: a PET symptom provocation study. *Neuropsychopharmacology* 27, 782–791
- 38 Yucel, M. *et al.* (2007) Functional and biochemical alterations of the medial frontal cortex in obsessive-compulsive disorder. *Arch. Gen. Psychiatry* 64, 946–955
- 39 Gilliam, C.M. and Tolin, D.F. (2010) Compulsive hoarding. *Bull. Menninger Clin.* 74, 93–121
- 40 Stern, E.R. *et al.* (2011) Hyperactive error responses and altered connectivity in ventromedial and frontoinsula cortices in obsessive-compulsive disorder. *Biol. Psychiatry* 69, 583–591
- 41 Fitzgerald, K.D. *et al.* (2010) Altered function and connectivity of the medial frontal cortex in pediatric obsessive-compulsive disorder. *Biol. Psychiatry* 68, 1039–1047
- 42 Chamberlain, S.R. *et al.* (2008) Orbitofrontal dysfunction in patients with obsessive-compulsive disorder and their unaffected relatives. *Science* 321, 421–422
- 43 Remijne, P.L. *et al.* (2006) Reduced orbitofrontal-striatal activity on a reversal learning task in obsessive-compulsive disorder. *Arch. Gen. Psychiatry* 63, 1225–1236
- 44 Bush, G. *et al.* (2002) Dorsal anterior cingulate cortex: a role in reward-based decision making. *Proc. Natl. Acad. Sci. U.S.A.* 99, 523–528
- 45 van Veen, V. and Carter, C.S. (2002) The anterior cingulate as a conflict monitor: fMRI and ERP studies. *Physiol. Behav.* 77, 477–482
- 46 Deckersbach, T. *et al.* (2002) A study of parallel implicit and explicit information processing in patients with obsessive-compulsive disorder. *Am. J. Psychiatry* 159, 1780–1782
- 47 Bush, G. and Shin, L.M. (2006) The Multi-Source Interference Task: an fMRI task that reliably activates the cingulo-frontal-parietal cognitive/attention network. *Nat. Protoc.* 1, 308–313
- 48 Pena-Garjón, J. *et al.* (2011) Involvement of the thalamic-cortical-striatal circuit in patients with obsessive-compulsive disorder during an inhibitory control task with reward and punishment contingencies. *J. Rev. Neurol.* 53, 77–86
- 49 Taylor, S.F. *et al.* (2007) Neural systems for error monitoring: recent findings and theoretical perspectives. *Neuroscientist* 13, 160–172
- 50 Gehring, W.J. and Knight, R.T. (2000) Prefrontal-cingulate interactions in action monitoring. *Nat. Neurosci.* 3, 516–520
- 51 Polli, F.E. *et al.* (2005) Rostral and dorsal anterior cingulate cortex make dissociable contributions during antisaccade error commission. *Proc. Natl. Acad. Sci. U.S.A.* 102, 15700–15705
- 52 Ursu, S. and Carter, C.S. (2005) Outcome representations, counterfactual comparisons and the human orbitofrontal cortex: implications for neuroimaging studies of decision-making. *Brain Res. Cogn. Brain Res.* 23, 51–60
- 53 Maltby, N. *et al.* (2005) Dysfunctional action monitoring hyperactivates frontal-striatal circuits in obsessive-compulsive disorder: an event-related fMRI study. *Neuroimage* 24, 495–503
- 54 Page, L.A. *et al.* (2009) A functional magnetic resonance imaging study of inhibitory control in obsessive-compulsive disorder. *Psychiatry Res.* 174, 202–209
- 55 Schlosser, R.G. *et al.* (2010) Fronto-cingulate effective connectivity in obsessive compulsive disorder: a study with fMRI and dynamic causal modeling. *Hum. Brain Mapp.* 31, 1834–1850
- 56 Buchel, C. *et al.* (1998) Brain systems mediating aversive conditioning: an event-related fMRI study. *Neuron* 20, 947–957
- 57 Linnman, C. *et al.* (2011) Unconditioned responses and functional fear networks in human classical conditioning. *Behav. Brain Res.* 221, 237–245
- 58 Milad, M.R. *et al.* (2007) A role for the human dorsal anterior cingulate cortex in fear expression. *Biol. Psychiatry* 62, 1191–1194
- 59 Dougherty, D.D. *et al.* (2002) Prospective long-term follow-up of 44 patients who received cingulotomy for treatment-refractory obsessive-compulsive disorder. *Am. J. Psychiatry* 159, 269–275
- 60 Perani, D. *et al.* (1995) [18F]FDG PET study in obsessive-compulsive disorder. A clinical/metabolic correlation study after treatment. *Br. J. Psychiatry* 166, 244–250
- 61 Davis, M. and Whalen, P.J. (2001) The amygdala: vigilance and emotion. *Mol. Psychiatry* 6, 13–34

- 62 Phan, K.L. *et al.* (2004) Functional neuroimaging studies of human emotions. *CNS Spectr.* 9, 258–266
- 63 Etkin, A. and Wager, T.D. (2007) Functional neuroimaging of anxiety: a meta-analysis of emotional processing in PTSD, social anxiety disorder, and specific phobia. *Am. J. Psychiatry* 164, 1476–1488
- 64 Britton, J.C. *et al.* (2006) Facial expressions and complex IAPS pictures: common and differential networks. *Neuroimage* 31, 906–919
- 65 Rauch, S.L. *et al.* (2003) Neuroimaging studies of amygdala function in anxiety disorders. *Ann. N.Y. Acad. Sci.* 985, 389–410
- 66 Shin, L.M. and Liberzon, I. (2010) The neurocircuitry of fear, stress, and anxiety disorders. *Neuropsychopharmacology* 35, 169–191
- 67 Milad, M.R. and Quirk, G.J. (2011) Fear extinction as a model for translational neuroscience: ten years of progress. *Annu. Rev. Psychol.*, in press.
- 68 Rauch, S.L. *et al.* (2006) Neurocircuitry models of posttraumatic stress disorder and extinction: human neuroimaging research: past, present, and future. *Biol. Psychiatry* 60, 376–382
- 69 Dilger, S. *et al.* (2003) Brain activation to phobia-related pictures in spider phobic humans: an event-related functional magnetic resonance imaging study. *Neurosci. Lett.* 348, 29–32
- 70 Ahs, F. *et al.* (2011) Arousal modulation of memory and amygdala-parahippocampal connectivity: a PET-psychophysiology study in specific phobia. *Psychophysiology* 48, 1463–1469
- 71 Wright, C.I. *et al.* (2003) Amygdala and insular responses to emotionally valenced human faces in small animal specific phobia. *Biol. Psychiatry* 54, 1067–1076
- 72 Mataix-Cols, D. *et al.* (2004) Distinct neural correlates of washing, checking, and hoarding symptom dimensions in obsessive-compulsive disorder. *Arch. Gen. Psychiatry* 61, 564–576
- 73 Britton, J.C. *et al.* (2010) Amygdala activation in response to facial expressions in pediatric obsessive-compulsive disorder. *Depress. Anxiety* 27, 643–651
- 74 Cardoner, N. *et al.* (2011) Enhanced brain responsiveness during active emotional face processing in obsessive compulsive disorder. *World J. Biol. Psychiatry* 12, 349–363
- 75 Shin, L.M. *et al.* (2011) Exaggerated activation of dorsal anterior cingulate cortex during cognitive interference: a monozygotic twin study of posttraumatic stress disorder. *Am. J. Psychiatry* 168, 979–985
- 76 Herry, C. *et al.* (2010) Neuronal circuits of fear extinction. *Eur. J. Neurosci.* 31, 599–612
- 77 Hofmann, S.G. *et al.* (2010) The empirical status of the ‘new wave’ of cognitive behavioral therapy. *Psychiatr. Clin. North Am.* 33, 701–710
- 78 Hermann, A. *et al.* (2007) Diminished medial prefrontal cortex activity in blood-injection-injury phobia. *Biol. Psychol.* 75, 124–130
- 79 Quirk, G.J. and Milad, M.R. (2010) Neuroscience: editing out fear. *Nature* 463, 36–37
- 80 Brunet, A. *et al.* (2011) Trauma reactivation under the influence of propranolol decreases posttraumatic stress symptoms and disorder: 3 open-label trials. *J. Clin. Psychopharmacol.* 31, 547–550
- 81 Hofmann, S.G. *et al.* (2006) Augmentation of exposure therapy with D-cycloserine for social anxiety disorder. *Arch. Gen. Psychiatry* 63, 298–304
- 82 Kushner, M.G. *et al.* (2007) D-cycloserine augmented exposure therapy for obsessive-compulsive disorder. *Biol. Psychiatry* 62, 835–838
- 83 Wilhelm, S. *et al.* (2008) Augmentation of behavior therapy with D-cycloserine for obsessive-compulsive disorder. *Am. J. Psychiatry* 165, 335–341 quiz 409
- 84 Storch, E.A. *et al.* (2010) A preliminary study of D-cycloserine augmentation of cognitive-behavioral therapy in pediatric obsessive-compulsive disorder. *Biol. Psychiatry* 68, 1073–1076
- 85 Greist, J.H. *et al.* (2003) WCA recommendations for the long-term treatment of obsessive-compulsive disorder in adults. *CNS Spectr.* 8 (Suppl. 1), 7–16
- 86 Greenberg, B.D. *et al.* (2010) Invasive circuitry-based neurotherapeutics: stereotactic ablation and deep brain stimulation for OCD. *Neuropsychopharmacology* 35, 317–336
- 87 Nuttin, B. *et al.* (2000) Electrical stimulation of the brain for psychiatric disorders. *CNS Spectr.* 5, 35–39
- 88 Greenberg, B.D. *et al.* (2010) Deep brain stimulation of the ventral internal capsule/ventral striatum for obsessive-compulsive disorder: worldwide experience. *Mol. Psychiatry* 15, 64–79
- 89 Rauch, S.L. *et al.* (2001) Cerebral metabolic correlates as potential predictors of response to anterior cingulotomy for obsessive compulsive disorder. *Biol. Psychiatry* 50, 659–667
- 90 Radua, J. *et al.* (2010) Meta-analytical comparison of voxel-based morphometry studies in obsessive-compulsive disorder vs other anxiety disorders. *Arch. Gen. Psychiatry* 67, 701–711
- 91 Radua, J. and Mataix-Cols, D. (2009) Voxel-wise meta-analysis of grey matter changes in obsessive-compulsive disorder. *Br. J. Psychiatry* 195, 393–402
- 92 Pujol, J. *et al.* (2004) Mapping structural brain alterations in obsessive-compulsive disorder. *Arch. Gen. Psychiatry* 61, 720–730
- 93 Cannistraro, P.A. *et al.* (2007) A diffusion tensor imaging study of white matter in obsessive-compulsive disorder. *Depress. Anxiety* 24, 440–446
- 94 Nakamae, T. *et al.* (2011) Diffusion tensor imaging and tract-based spatial statistics in obsessive-compulsive disorder. *J. Psychiatr. Res.* 45, 687–690
- 95 Saito, Y. *et al.* (2008) Corpus callosum in patients with obsessive-compulsive disorder: diffusion-tensor imaging study. *Radiology* 246, 536–542
- 96 Rauch, S.L. *et al.* (1997) Striatal recruitment during an implicit sequence learning task as measured by functional magnetic resonance imaging. *Hum. Brain Mapp.* 5, 124–132
- 97 Goldman, B.L. *et al.* (2008) Implicit learning, thought-focused attention and obsessive-compulsive disorder: a replication and extension. *Behav. Res. Ther.* 46, 48–61
- 98 van den Heuvel, O.A. *et al.* (2005) Frontal-striatal dysfunction during planning in obsessive-compulsive disorder. *Arch. Gen. Psychiatry* 62, 301–309
- 99 Balleine, B.W. and Dickinson, A. (1998) Goal-directed instrumental action: contingency and incentive learning and their cortical substrates. *Neuropharmacology* 37, 407–419
- 100 Gillan, C.M. *et al.* (2011) Disruption in the balance between goal-directed behavior and habit learning in obsessive-compulsive disorder. *Am. J. Psychiatry* 168, 718–726